



Research article

Histologic and histomorphometric evaluation of minicono abutment on implant surrounding tissue healing and bone resorption on implants placed in healed bone. An experimental study in dogs

José Luis Calvo-Guirado^{1,*}, Marta Belén Cabo-Pastor², Francisco Martínez-Martínez³, Miguel Ángel Garcés-Villalá⁴, Félix de Carlos-Villafranca⁵, Nuria García-Carrillo⁶ and Manuel Fernández-Domínguez⁷

¹ Department of Research, Health Sciences Faculty, Autonomous University of Chile, 7500912, Chile; Private Practice Murcia, Murcian Biomedical Research Institute, IMIB, Spain

² Department of Advanced Prosthodontics, Cardenal Herrera University, C.E.U, 46001 Valencia, Spain

³ Department of Traumatology, University Hospital Virgen of Arrixaca, 30120, El Palmar, Murcia, Murcian Biomedical Research Institute, IMIB, Spain

⁴ Department of Implant and Biomaterial Research, Jesus Heart Foundation, San Juan, 5400, Argentina

⁵ Department of Orthodontics, Faculty of Medicine, Oviedo University, 33001 Asturias, Spain

⁶ Department of Veterinary, University of Murcia, 30007 Murcia, Spain, Murcian Biomedical Research Institute, IMIB, Spain

⁷ Department of Dentistry, Camilo José Cela University, 28001 Madrid, Spain

* **Correspondence:** Email: joseluis.calvoguirado@gmail.com.

Abstract: The objective of this evaluation was to measure the width and length of connective tissue (CT) and crestal bone resorption (CBR) related to minicono® abutment inserted in conical connection dental implants, which were placed crestal and subcrestally in a dog's mandible. *Materials and Methods:* Forty-eight Top DM implants with the same coronal diameter were placed at the crestal level, 1 mm (test 1 group) and 2 mm (test 2 group) positions underneath buccal-lingual bone crests. Dental implants used in the study were separated into three groups of 16 implants each. The implants were randomly inserted into healed bone after two months post-extraction sockets of three lower premolars, and first molar, bilaterally in six male fox hound dogs. One 3 mm minicono height abutment

was connected to conical connection implants placed at the crestal level (control), 1 mm (test 1) and 2 mm (test 2) positions under buccal-lingual crests. *Results:* All abutments and implants used were clinically and histologically integrated into the bone-soft tissue. Soft tissue behavior was observed at eight and 12 weeks in all test groups, displaying similar quantitative findings with significant differences ($p > 0.05$). However, crestal bone loss was significantly greater at the buccal side around that control group compared to the test 1 and 2 groups. The difference values between groups at the implant shoulder to the top of the lingual bone crest (IS-LBC) and the implant shoulder to the top of the buccal bone crest (IS-BBC) were significantly greater for the test 2 group in comparison with the other two groups ($p < 0.05$) at eight weeks. In addition, crestal bone resorption (CBR) increased in the crestal group at twelve weeks, but it was reduced for the test 1 and test 2 groups in implants placed sub-crestally ($p < 0.05$). *Conclusions:* Crestal bone loss could be reduced using a 3 mm high abutment on implants submerged below the bone crest from 1 to 2 mm positions.

Keywords: collar design; implant placement; crestal placement; sub-crestal placement soft tissue height; minicono abutment; transmucosal abutment

1. Introduction

Maxillary and mandibular bones undergo significant resorption due to several problems, including poor patient hygiene, periodontal issues, and the need for a tooth extraction. Most of the resorption processes occur in the soft bone, which is cortical, especially in the vestibular wall of the alveolus, maintaining the bone structure through the lingual wall [1–4]. The height of the alveolar ridges, both buccal and lingual, have resorption in two phases and are stimulated by the implant surface over the entire neck treated with the implant surface [5]. Numerous factors act in animal experiments, such as implant insertion time, the type of dental implant, the insertion torque and depth, the insertion torque, the biological width settlement, and the design of the implant, which will act by itself, further influencing bone resorption [6–10]. Clinical and radiographic studies have suggested that surface treatment of the healing abutment and the final abutment of the prosthesis does not influence crestal bone loss around implants [11]. It was shown that the abutment implant union plays a fundamental role due to its design, which, in some cases, can act through micro-movements, which entails a loss of crestal bone, both buccal and lingual, and an increase in soft tissue [12]. This area can remodel itself in both thickness and height and is directly related to the size of the abutment, whether it is for healing or for the final abutment [12–14]. Placing a crestal implant between 1 and 2 mm restores the height and width dimensions of the gingival tissue around a healing abutment. The more coronal position of this soft tissue does not affect marginal bone loss; it maintains soft tissue thickness by acting as a protector of the alveolar ridges around the implant [12–14]. One of the fundamental factors is the design of the multiunit abutment, with a capacity for influencing the disposition of the collagen fibers in the perpendicular and oblique directions. Still, not all multiunit abutments have an ideal design. We previously published an article in which the use of wide healing abutments, that is, anatomical ones, increased the concentration of connective tissue, stimulating the orientation of the collagen fibers perpendicular and oblique to the soft tissue [15–18]. The best way to preserve the bundle bone is to determine the length and width stability of the connective tissue around the abutment, which is essential for long-term aesthetics in implants placed in the anterior sector [19,20]. Peri-implant bone

remodeling occurs mainly in the initial phases between 91 and 98 days after the first implant settlement, leading to subsequent alveolar bone preservation and enlargement of the soft tissue. As previously published by various authors, the platform switching technique stimulates bone protection by soft tissue establishment [20–22]. The main goal of this study is the evaluation of crestal bone loss when we connect a transepithelial abutment (minicono) screwed on implants located at different crestal levels (crestal, one and two mm under crestal bone). Our study aimed to assess if the implant position or the length of the transepithelial abutment (minicono) influences buccal or lingual plate bone loss.

2. Materials and methods

2.1. Project design

The animals used in the study were 6 Fox Hound dogs of approximately 1.5 years with an approximate weight of 15 to 18 kg. These animals were pre-emptively caged prior to surgical treatment under the care of a university veterinarian. They were fed a soft diet with adequate nutritional support during the length of the project. The animals received antibiotics (Enrofloxacin 5 mg/kg two times a day) and analgesics (Meloxicam 0.2 mg/kg, 3 times a day) via the systemic route after surgery. The clinical veterinary examination determined that the dogs were in good general health [13–16,21]. Forty-eight TOP DM® implants (Bioner, Sistemas Implantológicos, Barcelona, Spain) with the exact dimensions 3.5 mm diameter by 8.5 mm and one 3 mm height minicono® (Bioner Sistemas Implantológicos, Barcelona, Spain) abutment were used in the study.




Figure 1. (a) TOP DM implant; (b) minicono of 3 mm height abutment; (c) minicono® cover screw.

Two important variables were obtained during this study, representing the overall clinical results: position of the implant and the length of the minicono abutment.

2.1.1. Surgical procedure

All animals in the study underwent a prior anesthesia technique in the femoral quadriceps with acepromazine 0.13%–0.26 mg/kg, metomidine clorhydrate (35 µg/kg), and tolfelanic acid (1.5 mg/ml). Then, an intravenous catheter was inserted (diameter 22 G) into the cephalic vein of the animals and propofol at a concentration of 19.5 mg/kg (1,95 ml/kg) was administered. Dental infiltration anaesthesia was administered directly to premolar and molar areas (lidocaine 40 mg), as previously published [13–16,21]. The study design can be seen in Figure 2.

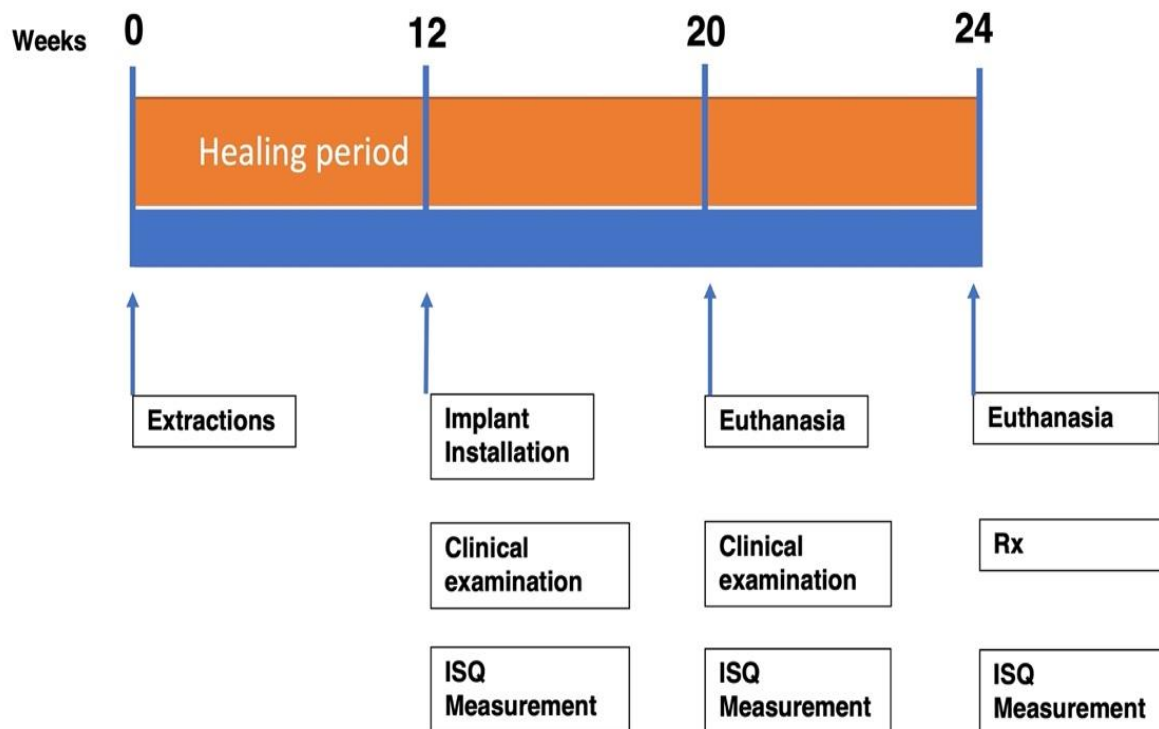


Figure 2. Outline of the study.

The surgical technique used to operate on the animals was supervised by the Chief Veterinarian of the University of Murcia. The extracted teeth were the lower premolars and the first molar bilaterally by odontosection (Figure 3a). Extraction areas were allowed to heal for 12 weeks before implant placement (Figure 3b). After three months of healing, 48 TOP DM implants 3.5×8.5 mm were randomly assigned crestally and subcrestally at 1- and 2-mm positions, placed with an insertion torque of ≥ 35 Ncm (Figure 3c). Dental implants were placed in the middle of the alveolus of extracted teeth, crestally and subcrestally at 1- and 2-mm positions (Figure 3d). Abutments at 3-mm in height were connected to the implants and screwed at 20 Ncm on each implant placed at the crestal and subcrestal levels (Figure 3e). Four implants were placed in each hemi-mandible with a cover screw on top of each minicono abutment (Figure 3f) and implant stability quotient (ISQ) values were measured with an Ostell Mentor Device (Goteborg Sweden) at implant installation (Day 0, eight and 12 weeks).

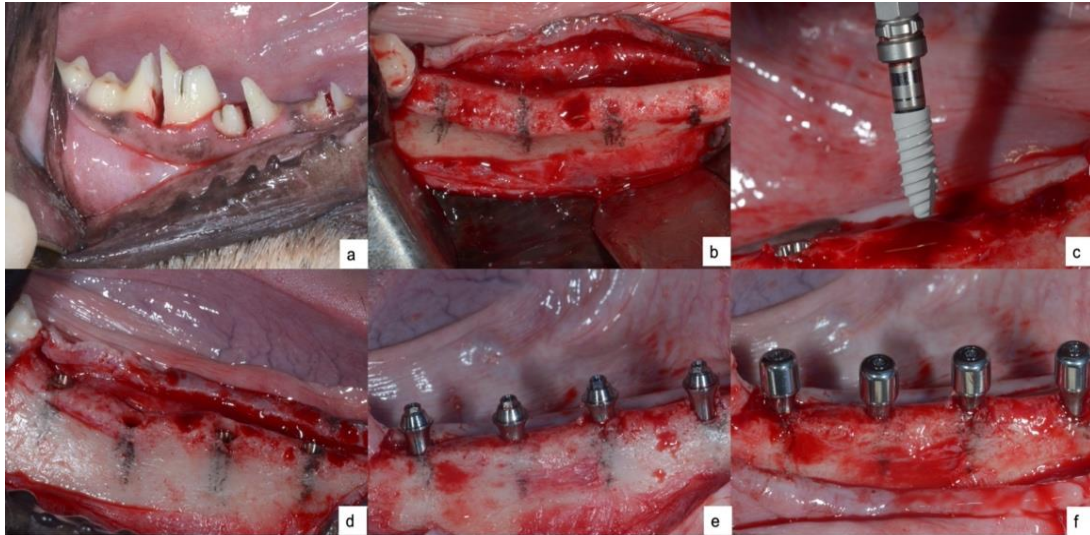


Figure 3. (a) premolar and molar odontosections; (b) healed bone after 12 weeks of healing; (c) Top DM implant; (d) dental implants placed crestally and subcrestally; (e) minicono abutments in place; (f) minicono cover screws before suture.

During the first week after surgery, the animals received the following antibiotics and analgesics via an oral route: clindamycin (300 mg, two times a day) and naproxen (600 mg, three times a day). The sutures were removed after two weeks by a veterinarian [13–16,21]. Three animals were sacrificed after eight weeks and the other three were scarified at 12 weeks ($n = 3$) with an overdose of pentothal natrium (Abbot Laboratories, Madrid, Spain) [13–16,21].

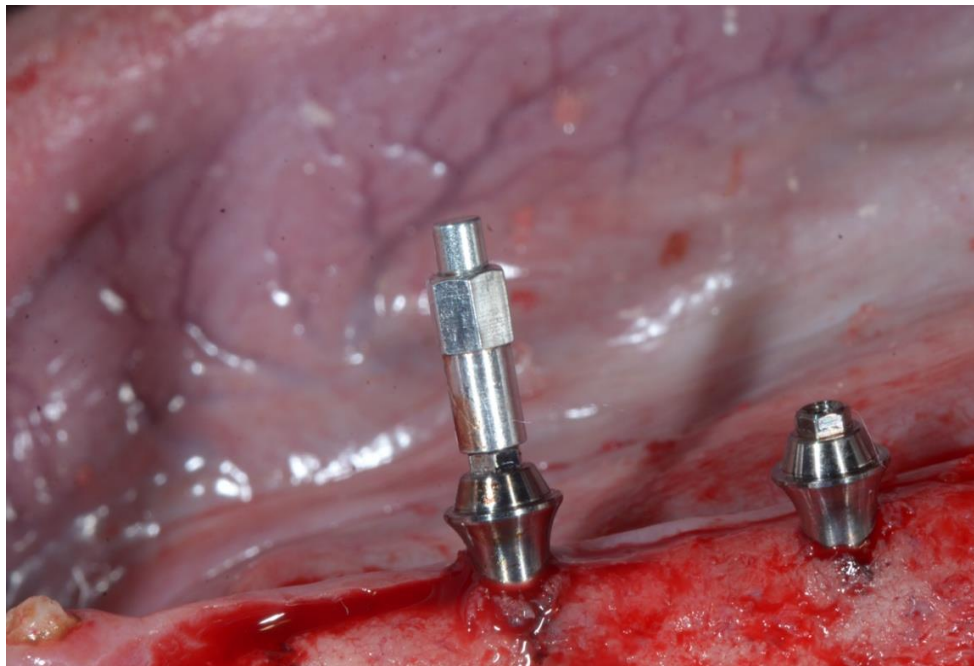


Figure 4. Smartpeg (Ostell mentor) connected to minicono abutment to evaluate implant stability.

2.1.2. Histological sample preparation

Each dog's implant with hard and soft tissues were divided into blocks and included in a fixing solution composed of 5% formalin. The samples were dehydrated with 1% ethanol and stored under vacuum [21]. Each of the samples were infiltrated with a special resin, called Technovit 7200® resin (Kulzer Heraeus, Germany), to fix the sample and to prepare the biopsy for analysis. The resin blocks were divided buccolingually parallel to the axis of the implant, making three different cuts. Each block was divided into four parts. Two fine blocks of 30 × 50 microns were produced for staining proposes with pricosirius-hematoxylin to distinguish between mature and immature bone. The other two thick blocks were later worn and polished for scanning electronic microscope. For a histomorphometry study, all images were enlarged at 20×, where eight different areas were analyzed using an Olympus DP 12 digital camera (Nagano, Japan) and the 4.0 micro-imaging software (Media Cybernetics, Silver Springs, USA) was used to analyze the samples. All samples were analyzed by the same lab technician to avoid bias [13–16,21].

2.1.3. Histomorphometric analysis

In all the biopsies performed, different marks were identified to evaluate the soft and hard tissue: implant shoulder (IS), buccal bone crest (BBC), lingual bone crest (LBC), Minicono shoulder (Mi), distance from first bone-to-implant contact-implant shoulder (A-IS), Buccal peri-implant mucosa (B-PIM), Lingual peri-implant mucosa (L-PIM), and the apical portion of the junction epithelium (Je) (Figure 5).

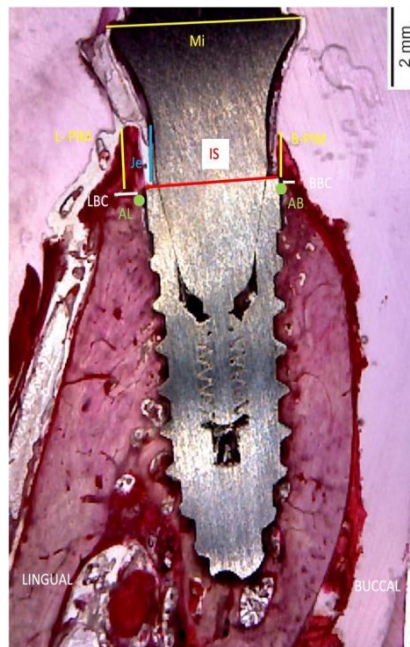


Figure 5. Landmarks of histologic evaluation: IS. Implant shoulder; AB: coronal bone-to-implant buccal area; AL: coronal bone-to-implant lingual contact area; Mi: minicono shoulder; BBC: buccal bone crest; LBC: lingual bone crest; Je junctional epithelium; B-PIM: buccal peri-implant mucosa; L-PIM: lingual peri-implant mucosa.

Measurement from high level of lingual peri-implant mucosa to the first bone-to-implant contact. Measured in millimetres. L-PIM-LBC.

Measurement from high level of buccal peri-implant mucosa to the first bone-to-implant contact. Measured in millimetres. B-PIM-BBC.

Measurement from the implant shoulder to the top of the buccal bone crest. Expressed as millimetres. IS-LBC.

Measurement from the implant shoulder to the top of the lingual bone crest. Measured in millimetres. IS-BBC.

Surrounding buccal mucosa length to implant shoulder. Measured in millimetres. B-PIM- IS.

Surrounding lingual mucosa length to implant shoulder. Measured in millimetres. L-PIM- IS.

Bone to implant contact BIC.

2.1.4. Digital radiographic evaluation

After the experiment was completed, each implant was individually and digitally radiographed in sections with two measurements: implant abutment junction (IAJ) and bone considering the lower level of crestal bone-to-implant contact. The same radiograph positioner was used in each radiograph and the images were repeated by the same surgeon three times. The radiographs were analyzed by the Newtom NTT Software (Newtom Cefla S.C., Imola Italia). All crestal bone measurements were performed in the mesial and distal directions to evaluate crestal bone loss between the minicono abutment and the implant connection. Radiographic measurements were made distally and mesially for each of the implants after an eight-week period and after 12 weeks for the implants placed crestally, both 1 and 2 mm below the crest level (Figure 6).

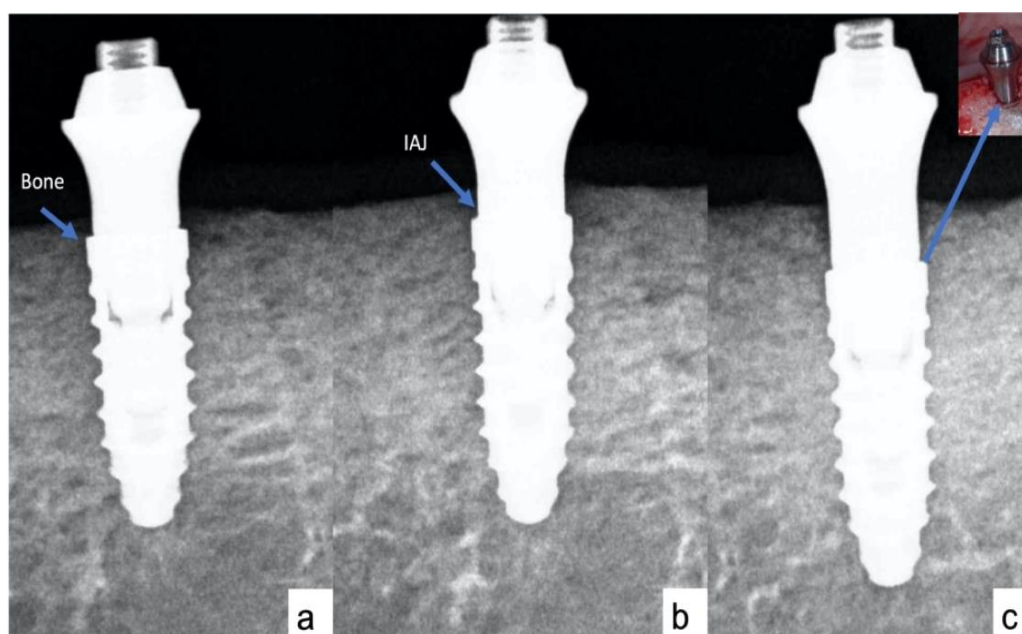


Figure 6. Digital periapical radiographs for the control implants, (a) control group; (b) test 1 group; (c) tests 2 group. Measurement between the implant abutment junction (IAJ) and the lower position of crestal bone-to-implant contact (Bone) was evaluated.

2.1.5. Implant stability evaluation (ISQ)

Measurements of implant stability were performed by an Osstell® Mentor device (W&H, Göteborg, Sweden) immediately on the day of surgery and at eight and 12 weeks after implant placement. Stability values were expressed in ISQ measurements six times in each implant and three times each on the buccolingual and mesiodistal surfaces.

2.1.6. Statistical analysis

The statistical study was carried out using the SPSS 21.0 software (SPSS, Chicago, IL, USA). Differences between two tests and one control implant with 3 mm high MINICONO sites were evaluated with a Wilcoxon test. A descriptive analysis was performed (mean and standard deviation) for both groups. A Friedman test was applied to compare the means with a significance level of 95% ($p < 0.05$). Bruner and Langer and Mann–Whitney U tests were applied to analyze the differences between the evaluation distances. The differences between groups ($n = 16$ control group, $n = 16$ test 1 group, $n = 16$ test 2 group) were made by means of repeated studies, considering only the dog as the dependent mean. The height and resorption of the alveolar ridges of the bone, as well as the height of the peri-implant mucosa, were expressed in absolute and relative terms.

2.1.7. Ethics approval of research

The University of Murcia ethics committee for Animal Research approved the study protocol number (A1320141102-04/11/2014), following European Union Council directive guidelines (Council 22 September 2010, 2010/63/EU).

3. Results

In addition, the following outcomes related to the radiographic evaluation, clinical and histological observations of hard and soft tissue and implant stability were explained in detail.

3.1. Radiographic evaluation

Implant healing at crestal placement bone loss was 1.22 ± 0.8 mm at mesial aspect and 1.24 ± 0.3 mm at distal aspect. This resorption was more than the bone loss of implants placed at a 2 mm subcrestal position, and was measured as 0.83 ± 1.7 mm at the distal position and 0.80 ± 1.4 mm at the mesial aspect of the test implant (Table 1). There are significant differences in bone loss between the control and test implants at eight and 12 weeks ($p = < 0.001$) in distal and mesial aspect, as calculated by the Mann-Whitney test (Table 1).

Table 1. All variables mean values for 2D aspect of each implant.

Placement Position	Mesial bone contact mean (mm) ±SD	Distal bone contact mean (mm) ±SD	Mesial difference mean (mm) ± SD	Distal difference mean (mm) ±SD	Mesial variables mean (mm) ±SD	Distal variables mean (mm) ±SD	p-value
Control group (8 weeks)	1.22 ±0.8	1.24 ±0.3	-1.425 ±0.4	-1.366 ± 0.2	-2.989 ±0.9	-2.872 ± 1.1	0.065
Test 1 group (8 weeks)	0.91 ±0.7	0.89 ±1.1	-1.217 ±0.2	-1.198 ± 0.5	-2.238 ±0.8	-2.241 ± 0.6	0.087
Test 2 groups (8 weeks)	0.81 ±0.6	0.85 ±0.7	-0.974 ±0.1	-0.986 ± 0.8	-1.986 ±0.4	-1.998 ± 0.2	0.123
Control group (12weeks)	1.26 ±1.1	1.28 ±0.9	-1.523 ±1.2	-1.401 ± 0.9	-3.021 ±0.1	-2.972 ± 0.8	0.055
Test 1 group (12 weeks)	0.96 ±0.9	0.92 ±0.4	-1.234 ±0.6	-1.241 ± 0.5	-2.245 ±0.4	-2.251 ±0.7	0.002*
Test 2 groups (12 weeks)	0.80 ±1.4	0.83 ±1.7	-0.982 ± 0.8*	-0.989 ± 1.2*	-1.994 ±0.1	-2.124 ± 0.7	0.002*

*Note: * Variances are assumed. Mesial- Distal differences = Initial to final mesial-distal variables mean values.

3.2. Histological and clinical evaluation

Surgical sites healed without any problem, and no healing abutment and implants were lost. The extensive junction epithelium (Je) was specially displayed in the lingual preimplant connective tissue of all samples obtained, and in direct contact with the minicono abutment. The buccal preimplant mucosa was less wide than the lingual one for all minicono abutments. At eight weeks, new build bone was observed around blood vessels on top of the buccal crest in the premolar areas, as well as a well-formed epithelium and connective tissue with less inflammatory tissue around the preimplant minicono area. In the control group, the peri-implant mucosa was composed with the thin epithelium, with a short connective tissue facing the titanium portion of the minicono abutment. At 12 weeks, the lingual bone wall suffered less bone resorption, and the soft tissue was better attached at the coronal region of the minicono abutment, while the buccal crest suffered more resorption. The abutment region showed parallel-fibered soft tissue and new established stable bone. The test groups exhibited signs of ongoing remodeling better than the control group due to minicono abutment protection (Figure 7).

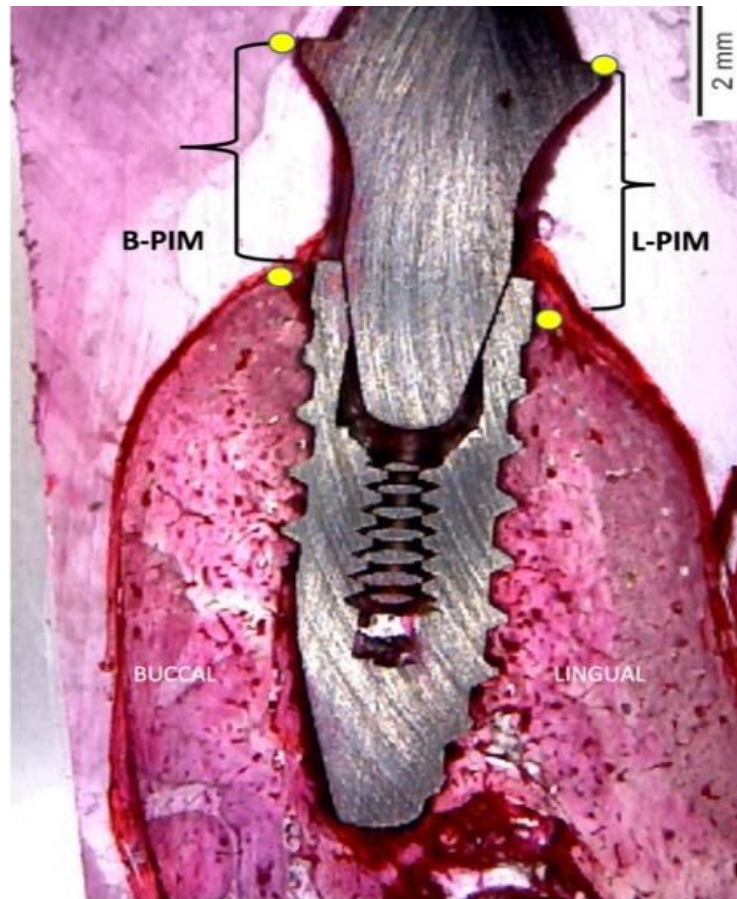


Figure 7. Soft tissue landmarks of histologic evaluation, B-PIM: buccal peri-implant mucosa; L-PIM: lingual peri-implant mucosa.

3.2.1. Soft tissue

8 weeks: The B-PIM-IS and L-PIM-IS measurements didn't show any significant differences related to soft tissue in-between test groups (Figure 7). The L-PIM-IS measurements showed no differences for the in-comparison group with the buccal site B-PIM-IS ($p < 0.05$) (Table 2).

12 weeks: All results at week 12 were superior to those found at week 8 in all evaluation groups. The L-PIM-IS measurements in the lingual and buccal areas didn't show any differences between the test groups ($p > 0.05$). The L-PIM-IS and B-PIM-IS measurements showed higher values for the lingual side in both groups in comparison with the buccal side ($p < 0.05$); the Je-C distance did not display any differences between the groups (Table 2).

Table 2. Non-parametric Man Whitney test was applied to median values set at $P < 0.05$.

Placement Position	BBC-LBC difference mean (mm) \pm SD	IS-BBC mean (mm) \pm SD	IS-AB mean (mm) \pm SD	IS-LBC mean (mm) \pm SD	IS-AL mean (mm) \pm SD	B-PIM- IS mean (mm) \pm SD	L-PIM- IS mean (mm) \pm SD
Crestal (8 w)	0.82 \pm 0.3	1.16 \pm 0.9	0.89 \pm 1.3	0.66 \pm 0.2	0.71 \pm 0.8	3.9 \pm 0.8	4.2 \pm 1.3
Subcrestal 1mm (8 w)	0.79 \pm 0.2	0.69 \pm 0.1	0.45 \pm 1.4	0.50 \pm 0.5	0.62 \pm 1.4	4.2 \pm 1.1	4.4 \pm 0.8
Subcrestal 2 mm (8 w)	0.77 \pm 0.2	0.62 \pm 0.7	0.33 \pm 0.9*	0.42 \pm 0.8	0.27 \pm 0.6*	4.4 \pm 1.8	4.6 \pm 0.4
Crestal (12 w)	0.81 \pm 1.8	1.24 \pm 1.3	0.92 \pm 1.6	0.78 \pm 0.6	0.74 \pm 0.7	3.8 \pm 1.1	4.1 \pm 0.3
Subcrestal 1 mm (12 w)	0.76 \pm 1.1	0.73 \pm 0.8	0.48 \pm 1.2	0.62 \pm 1.4	0.32 \pm 1.7	4.3 \pm 0.8	4.3 \pm 1.9
Subcrestal 2 mm (12 w)	0.74 \pm 1.7	0.66 \pm 1.55	0.45 \pm 1.6*	0.48 \pm 1.1	0.31 \pm 0.1*	4.9 \pm 0.8	4.8 \pm 0.4
<i>p</i> value	0.00652	0.0831	0.0012*	0.0678	0.0025*	0.7831	0.8721

Note: BBC-LBC, lingual and buccal bone crest; IS-BBC, measurement from implant collar to the buccal bone crest first contact; IS-AB, measurement from implant collar to first buccal bone area; IS-LBC, measurement from implant collar to lingual bone crest; IS-AL, measurement from implant collar to the lingual bone crest first contact; B-PIM- IS, buccal measurement of buccal mucosa attached to minicono abutment; L-PIM- IS, lingual measurement of buccal mucosa attached to minicono abutment; SD, Standard deviation. ($p < 0.05$ differences between values achieving statistical significance).

3.2.2. Hard tissue

8 weeks: The IS-B measurements in vestibular area were significantly higher in the control group when compared to both test groups ($p < 0.05$). No significant differences were observed in the lingual areas ($p > 0.05$) (Figure 8). The IS-C measurement was higher for the lingual and buccal areas of the control group when compared with the test 1 group ($p > 0.05$) (Table 1). The crestal implants showed an increased formation of woven bone in the coronal area (Figure 8a). The test 1 group showed larger amounts of newly formed bone with native bone within the coronal and body parts of the implant (Figure 8c). The most significant value was found in the test 2 group, showing increased bone implant contacts (Figure 8e). The connective tissue was located laterally on top of the minicono abutment at 1- and 2-mm positions below the crest level (Figure 8).

12 weeks: All measurements that were made at 12 weeks were increased in all groups (Figure 8). The IS-B buccal side measurements were significantly higher in the control group compared with the test groups ($p < 0.05$), and no significant differences were observed at the lingual areas ($p > 0.05$). The IS-C distance was augmented in the lingual and buccal zones of the control group when compared with the test groups ($p > 0.05$) (Table 1). After 12 weeks of healing, the entire implant surface was full surrounded with new bone in the test 1 and 2 groups when compared with the control group. The peri implant mucosa margin (PM) was located apically to the implant shoulder. At the lingual aspect of the implant, signs of the newly formed bone can be observed in the test 2 group (Figure 8f). The first bone-

to implant contact (BIC) at the lingual aspect is located close to the marginal level of the rough surface. After 12 weeks of healing, the buccal–lingual section of the crestal group showed that the margin of the peri implant mucosa is 2 mm below crest.

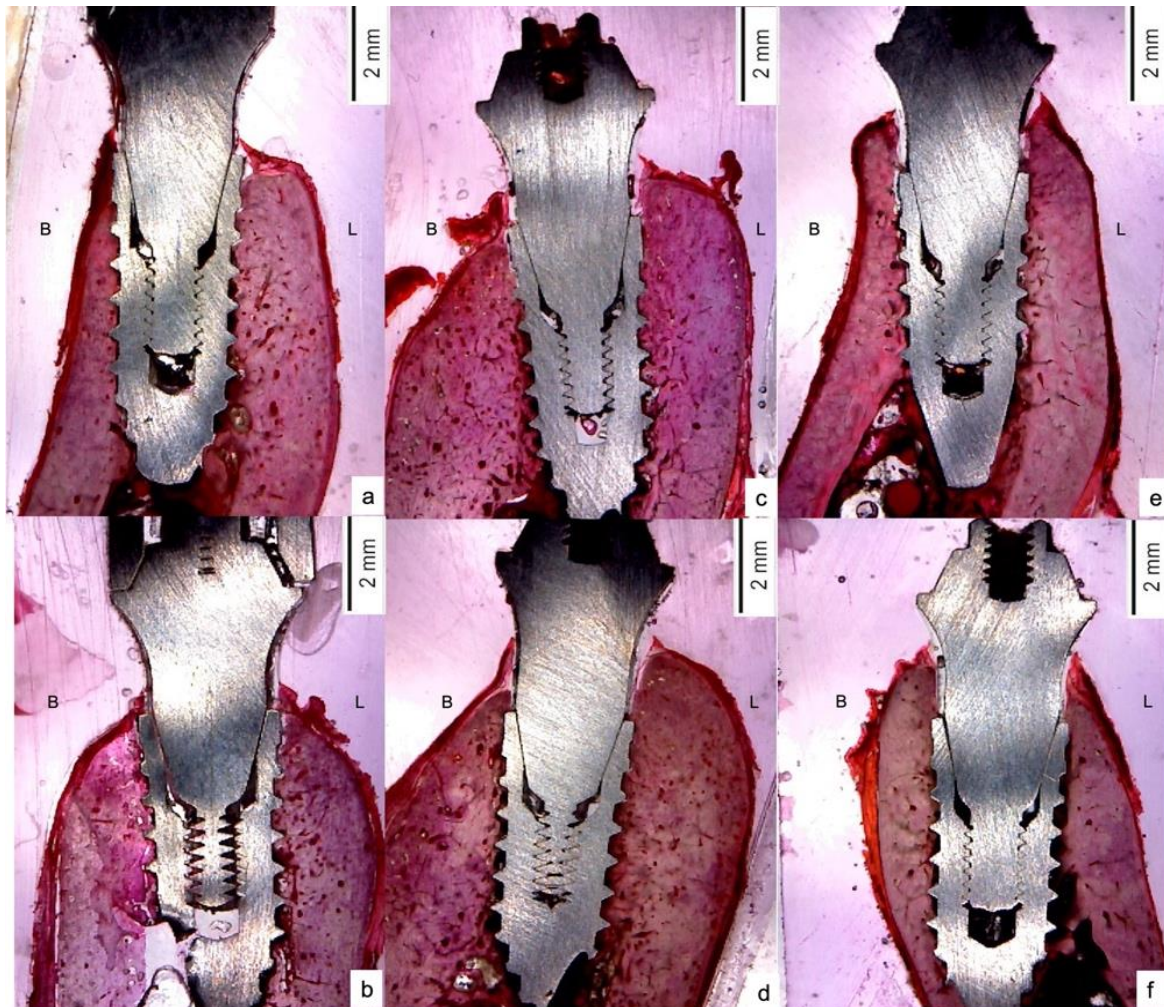


Figure 8. (a) eight weeks crestal placement; (b) twelve weeks crestal placement; (c) eight weeks at 1 mm below crest; (d) twelve weeks at test 1 group; (e) eight weeks at 2 mm below crest; (f) twelve weeks at test 2 group.

3.3. Bone to implant contact (BIC)

The total BIC in the test 1 and 2 groups were higher when compared with the control group at eight and 12 weeks. New formed bone in the coronal region was augmented in the test 2 group after eight weeks, and much greater after 12 weeks when compared to the test 1 and control groups. After evaluation, the coronal area (first BIC) was far away at the implant shoulder in the control group when compared to the test 1 and 2 groups (Table 3).

Table 3. Implant bone contact expressed in percentages \pm standard deviation [SD] at different periods of time.

Time of implant evaluation	Control group		Test 1 group		Test 2 group	
	mean values (%) + SD	<i>p</i> value	mean values (%) + SD	<i>p</i> value	mean values (%) + SD	<i>p</i> value
8 weeks	47.23 \pm 1.7	0.0672	50.98 \pm 1.5	0.0921	54.32 \pm 1.1	0.1236
12 weeks	43.65 \pm 1.9	0.0562	53.77 \pm 1.3	0.4321	57.89 \pm 1.2	0.7821

3.4. Implant stability quotient measurement (ISQ values)

ISQ values for the immediate implants showed significant intragroup differences at eight and 12 weeks in all groups. The test 2 group showed higher ISQ values (mean, 77.62 \pm 0.6) than the control group (mean, 72.09 \pm 0.6); however, at 12 weeks for the immediate implants, the test 2 group showed higher values at the P3 area of 79.2 \pm 0.9, which is different to control group value of 74.9 \pm 0.6, indicating no statistically significant intergroup difference (Table 4).

Table 4. Mean values for all ISQ values after implant placement, 8 and 12 weeks. * *p* < 0.05 statistical significance.

Placement position	M1 (First Molar)	P4 (4th premolar)	P3 (3rd premolar)	P2 (2nd premolar)
	ISQ values	ISQ values	ISQ values	ISQ values
	mean (mm) \pm SD	mean (mm) \pm SD	mean (mm) \pm SD	mean (mm) \pm SD
Control (Day 0)	71.44 \pm 0.2	72.09 \pm 0.6	73.02 \pm 0.3	73.87 \pm 0.4
Test 1 (Day 0)	74.23 \pm 0.7	76.52 \pm 0.1	70.08 \pm 0.6	70.12 \pm 0.9
Test 2 (Day 0)	75.24 \pm 0.1	77.62 \pm 0.6	75.54 \pm 0.8	73.75 \pm 0.8
Control (8 weeks)	72.66 \pm 0.7	73.24 \pm 0.1	74.01 \pm 0.8	74.01 \pm 0.6
Test 1 (8 weeks)	75.6 \pm 0.3	77.1 \pm 0.2	72.3 \pm 0.9	71.5 \pm 0.1
Test 2 (8 weeks)	77.3 \pm 0.2	78.2 \pm 0.1	76.5 \pm 0.9	74.8 \pm 1.4
Control (12 weeks)	74.8 \pm 1.3	75.7 \pm 0.7	74.9 \pm 0.6	75.1 \pm 0.3
Test 1 (12 weeks)	76.4 \pm 0.3	76.1 \pm 0.1	75.8 \pm 0.9	76.2 \pm 0.5
Test 2 (12 weeks)	78.3 \pm 0.1	78.8 \pm 0.3*	79.2 \pm 0.9*	77.9 \pm 0.5

The clinical outcomes assessed in the study showed that using the 3 mm minicono abutment in subcrestal implants could protect the bundle bone and reduce crestal bone loss.

4. Discussion

The multiunit abutments that are used in surgeries allow for the establishment of soft tissue, as well as its remodeling around it [23]. The modifications around soft tissue were directly related to the establishment of the conditions offered by either the definitive abutment or the healing abutment [17]. In some cases, the micro-threads of the implants may be related to the loss of marginal bone because they can free a space between the soft tissue and the abutment, which further allows for the entry of bacteria leading to bone resorption [17]. This formation of the biological width will depend on the minicono or multiunit abutment that is placed in our previous studies [8,13–17,21]. The use of healing multiunit abutments on top of the implants immediately after surgery didn't interfere into the connective tissue remodeling around them [23]. The biological width normally acted as a protector of the bone crests around the implant, as indicated mainly by the placement of the crystal of the implants, thus reducing the stress on the alveolar crests. However, the apical placement of the implants allows for a greater anchorage in the bone, improving the stability of the same increasing bone-implant contact [24]. Our studies on immediate post-extraction implants placed 1mm below the bone crest in experimental animals showed no influenced resorption of the surrounding bone walls after 12 weeks [25,26]. Many studies in which implants were placed at the coronal level with micro threads in the neck of the implant allowed for a restoration of the preimplant soft tissues under the neck of the implant [27]. The advantage of implants placed 1 mm under bone crest post extraction with a switched platform showed a reduction in the gap and the restoration of the biological width over the shoulder of the implants at 12 weeks, thereby protecting the crestal bone [28]. We defined placing the implants 2 mm under crest active implant surface, macro and microtopography, design and type of threads that help bone regeneration immediately and its apposition on the immediate implant [29–31]. However, the connective was influenced related to depth of the implant, thereby increasing its thickness and height, depending on the type of abutment that was placed [32,33]. Our study agreed with the data from Linkevicius et al., in 2020, where they showed that implant placement under the bone area considerably reduced bundle bone loss in a vertical direction, increasing the width of connective tissue to protect it [34]. The immediate placement of abutments, such as minicono on the implants, considerably reduced bone loss a month before the prosthesis was finished; however, after one year the difference between the groups was stable [35]. Madani et al. concluded that implants placed immediately or delayed with platform switching were the safest option for maintaining bone around the implants, placing the implants 1 mm below crestal bone, protecting and maintain the biological width [36]. It was shown that placing the 2 mm sub-crestal implants, where they find that the expanded platform implants lose more bone, is considerably reduced by increasing the soft thickness. In addition, implants located at the crestal level with platform switching considerably reduced the loss of bone and its surrounding structures such as soft tissue, thereby improving aesthetics [37]. They agreed with our work related to the placement of sub crestal implants that didn't influence the remodeling of soft and hard tissue. However, a decreased resorption in implants placed at crestal position led to an increase in bone implant contact (BIC), especially in cylindrical implants [6,7,38]. On the contrary, other studies spoke about the bone loss from the vestibular and lingual walls when the implants are under the crest; however, many of these studies were carried out in experimental animals, and its data can be cautiously transferred to humans [39–42]. In human studies, the main parameters to be considered are the height of the crestal bone and the implant location above or below the bone level [43]. The evaluation of those parameters must be supported by a radiographic clinical study and the

inflammatory immune response related to implant type, macro design, length and position [43–48]. We concluded that implants with a minicono abutment placed 2 mm below crest in healed bone stimulated a soft tissue response to the width and height and protected bundle bone. Our findings guided clinical practitioners with the potential implications for implant placement location, especially sub-crestal and the minicono abutment for soft tissue and bone establishment.

5. Conclusions

In our conclusions, we can affirm that despite the limitations of an experimental study, bone resorption can be controlled if we place the implants 1 or 2 mm under the bone crest. The use of the minicono abutment minimizes bone loss, favors the restoration of the biological width by increasing the thickness and height of the connective tissue that sits directly on implant surface. The conformation of that soft tissue that we have found around a 3mm polished abutment were similar in both groups of implants placed 1 and 2mm below the crest. On the other hand, implants placed at crestal level soft tissue moved down minicono abutment reaching a new peri-implant mucosa establishment.

Use of AI tools declaration

The authors declare they have not used Artificial Intelligence (AI) tools in the creation of this article.

Conflict of interest

I am an editorial board and I was not involved in the editorial review or the decision to publish this article. All authors declare that there are no competing interests.

Author contributions

Conceptualization, J.L.C.-G. and F.M.-M.; data curation, M.B.C-P, N.G-C; formal analysis, F.d.C.-V. and M.A.G-V.; funding acquisition, J.L.C.-G., F.M.-M., and M.F.-D.; investigation, J.L.C.-G, N.G-C.; software, F.d.C.-V. and M.A.G.-V.; methodology, F.M.-M., F.d.C.-V., M.B.C-P; project administration, J.L.C.-G.; resources, F.M.-M.; supervision, J.L.C.-G. and F.M.-M.; validation, M.F.-D and M.B.C.-P.; visualization, J.L.C.-G., N.G-C and F.M.-M; writing—original draft preparation, J.L.C.-G. and F.M.-M.; writing—review and editing, J.L.C.-G., F.d.C.-V., M.B.C.-P., F.d.C.-V, M.F.-D. All authors have read and agreed to the published version of the manuscript.

References

1. Wang RE, Lang NP (2012) Ridge preservation after tooth extraction. *Clin Oral Implants Res* 23: 147–156. <https://doi.org/10.1111/j.1600-0501.2012.02560.x>
2. Araújo MG, Sukekava F, Wennström JL, et al. (2005) Ridge alterations following implant placement in fresh extraction sockets: an experimental study in the dog. *J Clin Periodontol* 32: 645–652. <https://doi.org/10.1111/j.1600-051X.2005.00726.x>

3. Araújo MG, Lindhe J (2005) Dimensional ridge alterations following tooth extraction. An experimental study in the dog. *J Clin Periodontol* 32: 212–218. <https://doi.org/10.1111/j.1600-051X.2005.00642.x>
4. Botticelli D, Berglundh T, Lindhe J (2004) Hard-tissue alterations following immediate implant placement in extraction sites. *J Clin Periodontol* 31: 820–828. <https://doi.org/10.1111/j.1600-051X.2004.00565.x>
5. Welander M, Abrahamsson I, Berglundh T (2009) Placement of two-part implants in sites with different buccal and lingual bone heights. *J Periodontol* 80: 324–329. <https://doi.org/10.1902/jop.2009.080375>
6. Negri B, Calvo-Guirado JL, Pardo-Zamora G, et al. (2012) Retracted: Peri-implant bone reactions to immediate implants placed at different levels in relation to crestal bone. Part I: a pilot study in dogs. *Clin Oral Implants Res* 23: 228–235. <https://doi.org/10.1111/j.1600-0501.2011.02158.x>
7. Negri B, Calvo-Guirado JL, Ramírez-Fernández MP, et al. (2012) Retracted: Peri-implant bone reactions to immediate implants placed at different levels in relation to crestal bone. Part II: a pilot study in dogs. *Clin Oral Implants Res* 23: 236–244. <https://doi.org/10.1111/j.1600-0501.2011.02290.x>
8. Calvo-Guirado JL, Aguilar-Salvatierra A, Gomez-Moreno G, et al. (2014) Histological, radiological and histomorphometric evaluation of immediate vs. non-immediate loading of a zirconia implant with surface treatment in a dog model. *Clin Oral Implants Res* 25: 826–830. <https://doi.org/10.1111/clr.12145>
9. Degidi M, Piattelli A, Scarano A, et al. (2012). Peri-implant collagen fibers around human cone Morse connection implants under polarized light: a report of three cases. *Int J Periodont Res Dent* 32: 323–328.
10. Fickl S, Zuhr O, Stein JM, et al. (2010) Peri-implant bone level around implants with platform-switched abutments. *Int J Oral Max Impl* 25: 577–581.
11. Valles C, Rodríguez-Ciurana X, Nart J, et al. (2017) Influence of implant neck surface and placement depth on crestal bone changes around platform-switched implants: A clinical and radiographic study in dogs. *J Periodontol* 88: 1200–1210. <https://doi.org/10.1902/jop.2017.170192>
12. Calvo-Guirado JL, Gómez-Moreno G, López-Marí L, et al. (2011) Crestal bone loss evaluation in osseotite expanded platform implants: a 5-year study. *Clin Oral Implants Res* 22: 1409–1414. <https://doi.org/10.1111/j.1600-0501.2010.02130.x>
13. Calvo-Guirado JL, Ortiz-Ruiz AJ, Negri B, et al. (2010) Histological and histomorphometric evaluation of immediate implant placement on a dog model with a new implant surface treatment. *Clin Oral Implants Res* 21: 308–315. <https://doi.org/10.1111/j.1600-0501.2009.01841.x>
14. Calvo-Guirado JL, Cambra J, Tarnow DP (2009) The effect of interimplant distance on the height of the interimplant bone crest when using platform-switched implants. *Int J Periodontics Restorative Dent* 29: 141–151.
15. Delgado-Ruiz RA, Calvo-Guirado JL, Abboud M, et al. (2015) Connective tissue characteristics around healing abutments of different geometries: new methodological technique under circularly polarized light. *Clin Implant Dent R* 17: 667–680. <https://doi.org/10.1111/cid.12161>
16. Delgado-Ruiz RA, Calvo-Guirado JL, Abboud M, et al. (2015) Connective tissue characteristics around healing abutments of different geometries: new methodological technique under circularly polarized light. *Clin Implant Dent R* 17: 667–680. <https://doi.org/10.1111/cid.12161>

17. Negri B, Calvo Guirado JL, Maté Sánchez de Val JE, et al. (2014) Peri-implant tissue reactions to immediate nonocclusal loaded implants with different collar design: an experimental study in dogs. *Clin Oral Implants Res* 25: e54–e63. <https://doi.org/10.1111/clar.12047>
18. Froum SJ, Cho SC, Suzuki T, et al. (2018) Epicrestal and subcrestal placement of platform-switched implants: 18 month-result of a randomized, controlled, split-mouth, prospective clinical trial. *Clin Oral Implants Res* 29: 353–366. <https://doi.org/10.1111/clar.13129>
19. Mangano F, Mangano C, Ricci M, et al. (2012) Single-tooth Morse taper connection implants placed in fresh extraction sockets of the anterior maxilla: an aesthetic evaluation. *Clin Oral Implants Res* 23: 1302–1307. <https://doi.org/10.1111/j.1600-0501.2011.02307.x>
20. Donovan R, Fetner A, Koutouzis T, et al. (2010) Crestal bone changes around implants with reduced abutment diameter placed non-submerged and at subcrestal positions: A 1-year radiographic evaluation. *J Periodontol* 81: 428–434. <https://doi.org/10.1902/jop.2009.090317>
21. Rodríguez X, Vela X, Calvo-Guirado JL, et al. (2012) Effect of platform switching on collagen fiber orientation and bone resorption around dental implants: a preliminary histologic animal study. *Int J Oral Maxillofac Implants* 27: 1116–1122.
22. Oskarsson M, Otsuki M, Welander M, et al. (2018) Peri-implant tissue healing at implants with different designs and placement protocols: an experimental study in dogs. *Clin Oral Implants Res* 29: 873–880. <https://doi.org/10.1111/clar.13339>
23. Francisco H, Finelle G, Bornert F, et al. (2021) Peri-implant bone preservation of a novel, self-cutting, and fully tapered implant in the healed crestal ridge of minipigs: submerged vs. transgingival healing. *Clin Oral Invest* 25: 6821–6832. <https://doi.org/10.1007/s00784-021-03970-0>
24. Nagarajan B, Murthy V, Livingstone D, et al. (2015) Evaluation of crestal bone loss around implants placed at equicrestal and subcrestal levels before loading: a prospective clinical study. *J Clin Diagn Res* 9: ZC47–ZC50. <https://doi.org/10.7860/JCDR/2015/13911.7000>
25. Calvo-Guirado JL, Boquete-Castro A, Negri B, et al. (2014) Crestal bone reactions to immediate implants placed at different levels in relation to crestal bone. A pilot study in Foxhound dogs. *Clin Oral Impl Res* 25: 344–351. <https://doi.org/10.1111/clar.12110>
26. Sotto-Maior BS, Lima CA, Senna PM, et al. (2014) Biomechanical evaluation of subcrestal dental implants with different bone anchorages. *Braz Oral Res* 28: 1–7. <https://doi.org/10.1590/1807-3107BOR-2014.vol28.0023>
27. Cochran DL, Mau LP, Higginbottom FL, et al. (2013) Soft and hard tissue histologic dimensions around dental implants in the canine restored with smaller-diameter abutments: a paradigm shift in peri-implant biology. *Int J Oral Max Impl* 28: 494–502. <https://doi.org/10.11607/jomi.3081>
28. de Val JEMS, Gómez-Moreno G, Ruiz-Linares M, et al. (2017) Effects of surface treatment modification and implant design in implants placed crestal and subcrestally applying delayed loading protocol. *J Craniofac Surg* 28: 552–558. <https://doi.org/10.1097/SCS.0000000000003209>
29. Calvo-Guirado JL, López-López PJ, Mate Sanchez JE, et al. (2014) Crestal bone loss related to immediate implants in crestal and subcrestal position: a pilot study in dogs. *Clin Oral Implants Res* 25: 1286–1294. <https://doi.org/10.1111/clar.12267>

30. Calvo-Guirado JL, Delgado Ruiz RA, Ramírez-Fernández MP, et al. (2016) Retracted: Histological and histomorphometric analyses of narrow implants, crestal and subcrestally placed in severe alveolar atrophy: a study in foxhound dogs. *Clin Oral Implants Res* 27: 497–504. <https://doi.org/10.1111/clar.12569>
31. Sánchez-Siles M, Muñoz-Cámara D, Salazar-Sánchez N, et al. (2018) Crestal bone loss around submerged and non-submerged implants during the osseointegration phase with different healing abutment designs: a randomized prospective clinical study. *Clin Oral Implants Res* 29: 808–812. <https://doi.org/10.1111/clar.12981>
32. De Siqueira RAC, Savaget Goncalves Junior R, Dos Santos PGF, et al. (2020) Effect of different implant placement depths on crestal bone levels and soft tissue behavior: a 5-year randomized clinical trial. *Clin Oral Implants Res* 31: 282–293. <https://doi.org/10.1111/clar.13569>
33. de Siqueira RAC, Fontão FNGK, Sartori IAM, et al. (2017) Effect of different implant placement depths on crestal bone levels and soft tissue behavior: a randomized clinical trial. *Clin Oral Implants Res* 28: 1227–1233. <https://doi.org/10.1111/clar.12946>
34. Linkevicius T, Puisys A, Linkevicius R, et al. (2020) The influence of submerged healing abutment or subcrestal implant placement on soft tissue thickness and crestal bone stability. A 2-year randomized clinical trial. *Clin Implant Dent R* 22: 497–506. <https://doi.org/10.1111/cid.12903>
35. Linkevicius T, Linkevicius R, Gineviciute E, et al. (2021) The influence of new immediate tissue level abutment on crestal bone stability of subcrestally placed implants: A 1-year randomized controlled clinical trial. *Clin Implant Dent R* 23: 259–269. <https://doi.org/10.1111/cid.12979>
36. Madani E, Smeets R, Freiwald E, et al. (2018) Impact of different placement depths on the crestal bone level of immediate versus delayed placed platform-switched implants. *J Craniomaxillofac Surg* 46: 1139–1146. <https://doi.org/10.1016/j.jcms.2018.05.001>
37. Uraz A, Isler S C, Cula S, et al. (2019) Platform-switched implants vs platform-matched implants placed in different implant-abutment interface positions: A prospective randomized clinical and microbiological study. *Clin Implant Dent R* 22: 59–68. <https://doi.org/10.1111/cid.12873>
38. Fernández-Domínguez M, Ortega-Asensio V, Fuentes Numancia E, et al. (2019) Can the macrogeometry of dental implants influence guided bone regeneration in buccal bone defects? Histomorphometric and biomechanical analysis in beagle dogs. *J Clin Med* 8: 618. <https://doi.org/10.3390/jcm8050618>
39. Pellicer-Chover H, Peñarrocha-Diago M, Peñarrocha-Oltra D, et al. (2016) Impact of crestal and subcrestal implant placement in peri-implant bone: a prospective comparative study. *Med Oral Patol Oral Cir Bucal* 21: e103–e110. <https://doi.org/10.4317/medoral.20747>
40. Cruz RS, Lemos CAA, de Luna Gomes JM, et al. (2022) Clinical comparison between crestal and subcrestal dental implants: a systematic review and meta-analysis. *J Prosthet Dent* 127: 408–417. <https://doi.org/10.1016/j.prosdent.2020.11.003>
41. Palacios-Garzón N, Velasco-Ortega E, López-López J (2019) Bone loss in implants placed at subcrestal and crestal level: a systematic review and meta-analysis. *Materials* 12: 154. <https://doi.org/10.3390/ma12010154>
42. Valles C, Rodríguez-Ciurana X, Clementini M, et al. (2018) Influence of subcrestal implant placement compared with equicrestal position on the peri-implant hard and soft tissues around platform-switched implants: a systematic review and meta-analysis. *Clin Oral Invest* 22: 555–570. <https://doi.org/10.1007/s00784-017-2301-1>

43. Tenenbaum H, Schaaf JF, Cuisinier FJ (2003) Histological analysis of the Ankylos peri-implant soft tissues in a dog model. *Implant Dent* 12: 259–265. <https://doi.org/10.1097/01.ID.0000075720.78252.54>
44. Al Amri MD (2016) Crestal bone loss around submerged and nonsubmerged dental implants: a systematic review. *J Prosthet Dent* 115: 564–570. <https://doi.org/10.1016/j.prosdent.2015.11.002>
45. Al Amri MD, Alfadda SA, Labban NY, et al. (2018) Comparison of clinical, radiographic, and immunologic inflammatory parameters around crestally and subcrestally placed dental implants: 5-year retrospective results. *J Prosthodont* 27: 3–9. <https://doi.org/10.1111/jopr.12637>
46. Koutouzis T, Adeinat B, Ali A (2019) The influence of abutment macro-design on clinical and radiographic peri-implant tissue changes for guided, placed, and restored implants: a 1-year randomized controlled trial. *Clin Oral Implants Res* 30: 882–891. <https://doi.org/10.1111/clr.13493>
47. Fetner M, Fetner A, Koutouzis T, et al. (2015) The effects of subcrestal implant placement on crestal bone levels and bone-to-abutment contact: A microcomputed tomographic and histologic study in dogs. *Int J Oral Maxillofac Implants* 30: 1068–1075. <https://doi.org/10.11607/jomi.4043>
48. Thoma DS, Jung UW, Gil A, et al. (2019) The effects of hard and soft tissue grafting and individualization of healing abutments at immediate implants: an experimental study in dogs. *J Periodontal Implant Sci* 49: 171–184. <https://doi.org/10.5051/jpis.2019.49.3.171>



AIMS Press

© 2023 the Author(s), licensee AIMS Press. This is an open access article distributed under the terms of the Creative Commons Attribution License (<http://creativecommons.org/licenses/by/4.0>).